

Large bowel pneumatosis intestinalis: to operate or not to operate?

Jean-Loup Gassend, Maria Dimitrief, Daniel Roulet, Floryn Cherbanyk

Department of General Surgery, Hôpital Riviera-Chablais, Montreux, Switzerland

Correspondence to
Dr Floryn Cherbanyk,
floryn.cherban@yahoo.fr

Accepted 9 March 2016

DESCRIPTION

A 72-year-old patient with a history of chronic obstructive pulmonary disease (COPD) and hepatitis B, presented to the emergency room, with abdominal pain that had started 6 h previously, accompanied by nausea, vomiting and a 38.8°C fever. Clinical examination revealed generalised peritonitis. Lab results showed increased C reactive protein at 66 mg/L (normal value <7.5) and leukocytosis at 21.6 giga/L (normal value 4.0–10.0).

Abdominal X-ray showed signs of colic pneumatosis (figure 1). This was confirmed by CT scan, which also showed the existence of a discrete pneumoperitoneum and the presence of a moderate amount of free fluid (figure 2).

In view of this clinical and paraclinical picture, an explorative laparotomy was performed, revealing widespread colic pneumatosis starting at the caecum and extending all the way to the sigmoid (figure 3). The presence of cloudy peritoneal fluid was also noted. A careful examination of the bowels was performed, but no perforation was found. A subtotal colectomy with mechanical ileosigmoid anastomosis was performed. An ulcerative-like perforation was discovered in the transverse colon during postoperative examination of the specimen (figure 4A,B). The final diagnosis after pathological examination was determined to be

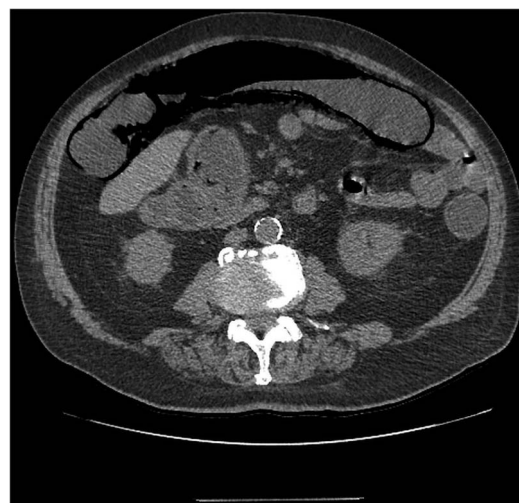

Figure 2 Axial plane CT scan of the abdomen showing pneumatosis intestinalis.

pneumatosis cystoides intestinalis with one ulcerative-like ischaemic perforation. The patient made an uneventful recovery and was discharged on day 7.

Pneumatosis is a rare disease characterised by the presence of gas in the submucosa and subserosa of the bowel. In a retrospective review published by Koss¹ in 1952, 15% of cases of pneumatosis intestinalis were classified as primary or idiopathic, and 85% were considered secondary. Traditionally, pneumatosis intestinalis was considered to require operative treatment, however, Morris² reports that up to 50% of cases can be managed non-operatively. Surgery is advised in cases presenting

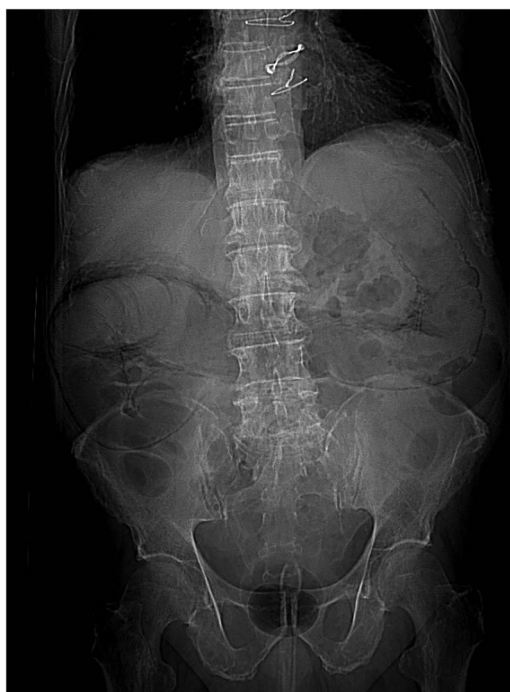

Figure 1 Abdominal X-ray showing signs of pneumatosis intestinalis.

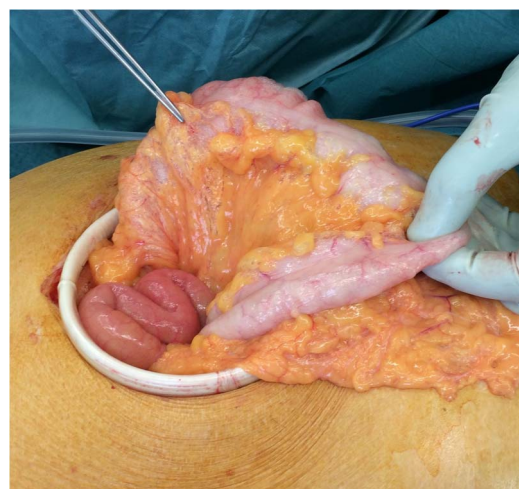
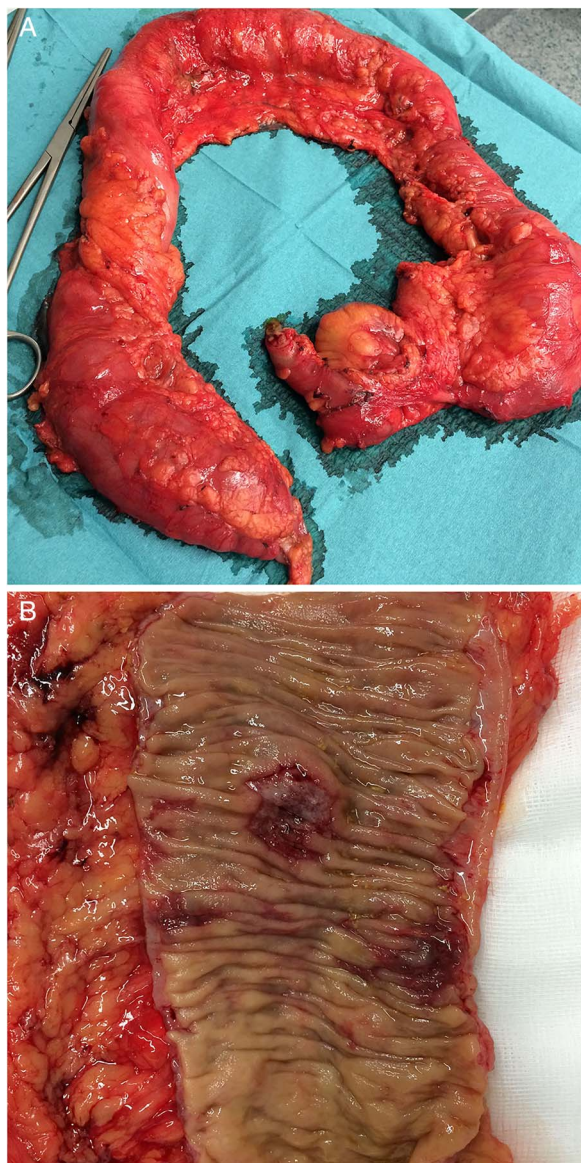


Figure 3 Pneumatosis of the colon visible during laparotomy.



CrossMark

To cite: Gassend J-L, Dimitrief M, Roulet D, et al. *BMJ Case Rep* Published online: [please include Day Month Year] doi:10.1136/bcr-2016-214612



Figures 4 (A and B) Operative specimen, with ulcerative-like perforation of the transverse colon.

with obstruction or acute abdomen. In the patient described here, operative treatment was planned based on the clinical picture and the presence of free fluid.

Learning points

- Management of pneumatosis intestinalis can be operative or conservative, the decision should be based on the clinical and radiological pictures.
- Surgical management is normally required in the presence of an acute abdomen.
- Most cases of pneumatosis intestinalis are secondary to other pre-existing pathologies.

Contributors J-LG, MD and FC were responsible for database search and writing of the article. DR and FC performed the surgery. DR was responsible for correction of the article and supervision.

Competing interests None declared.

Patient consent Obtained.

Provenance and peer review Not commissioned; externally peer reviewed.

REFERENCES

- 1 Koss LG. Abdominal gas cysts (pneumatosis systoides intestinorum hominis); an analysis with a report of a case and critical review of the literature. *AMA Arch Pathol* 1952;53:523–49.
- 2 Morris MS, Gee AC, Cho SD, *et al.* Management and outcome of pneumatosis intestinalis. *Am J Surg* 2008;195:679–82; discussion 682–3.

Copyright 2016 BMJ Publishing Group. All rights reserved. For permission to reuse any of this content visit <http://group.bmj.com/group/rights-licensing/permissions>.
BMJ Case Report Fellows may re-use this article for personal use and teaching without any further permission.

Become a Fellow of BMJ Case Reports today and you can:

- Submit as many cases as you like
- Enjoy fast sympathetic peer review and rapid publication of accepted articles
- Access all the published articles
- Re-use any of the published material for personal use and teaching without further permission

For information on Institutional Fellowships contact consortiasales@bmjgroup.com

Visit casereports.bmj.com for more articles like this and to become a Fellow